

Clinical Evaluation of Dental Implants with Surfaces Roughened by Anodic Oxidation, Dual Acid-Etched Implants, and Machined Implants

Alexandre-Amir Aalam, DDS¹/Hessam Nowzari, DDS, PhD²

Purpose: The purpose of this study was the clinical and radiographic comparison of dental implants with surfaces roughened by anodic oxidation (TiUnite), dual acid-etched implants (Osseotite), and machined implants. **Materials and Methods:** Seventy-four patients (mean age, 52.8 ± 14.2 years; range, 23 to 80 years; 41 men and 33 women) received 198 dental implants—58 TiUnite implants (25 patients), 52 Osseotite implants (27 patients), and 88 machined implants (22 patients). Clinical measurements and radiographs were evaluated at the time of surgery, at the restorative phase, and 2 years postloading. To account for statistical correlation among multiple implants in the same subject, a “per patient” mode of analysis was conducted. A 1-way analysis of variance of bone loss was conducted by type of implant as well by area of the mouth. In addition, differences in mean bone loss were tested for bone density category, gender, and smoking status using Student t tests. **Results:** Eighteen TiUnite implants (31.0%) were placed in the maxilla and 40 (69.0%) in the mandible. The Osseotite group included 29 maxillary implants (55.8%) and 23 mandibular implants (44.2%). The machined group included 49 maxillary implants (55.7%) and 39 mandibular implants (44.3%). All 198 implants were considered radiographically and clinically successful. No mobility, signs of infection, or inflammation were detected. **Discussion:** Implant size, location, bone quality, gender, age, and smoking did not influence the comparative clinical outcomes of the 3 groups ($P > .05$). A trend toward greater coronal bone loss in the TiUnite group was detected. **Conclusion:** Within the limitations of the present study, TiUnite, Osseotite, and machined dental implants had similar short-term clinical outcomes. No statistically significant differences in bone loss could be detected among implant groups or among the different regions of the oral cavity. The present data underlined the significance of surgical and prosthetic treatment planning. INT J ORAL MAXILLOFAC IMPLANTS 2005;20:793–798

Key words: anodic oxidation, dental implants, dual acid-etched implants, implant surfaces

In the initially proposed tenets for obtaining osseointegration, the placement of commercially pure smooth surface titanium screw-type implants into the viable bone of completely edentulous maxillae or mandibles with a submerged healing period

was advocated.^{1,2} Currently, implant utilization has expanded to include fixed partial dentures (FPDs), single-tooth replacement,³ and maxillofacial applications.⁴ Immediate implant placement after tooth extraction,^{5–9} stability in low-density bone,¹⁰ reduction of the healing period,¹¹ and the use of single-stage procedures^{12,13} have increased the challenge of implant biomechanical properties. To accommodate the new clinical applications of modern implant dentistry, manufacturers have modified the macrostructures (eg, tapered, conical/tapered, ovoid)¹⁴ and the microstructures (eg, titanium plasma-sprayed, hydroxyapatite-coated, titanium oxide [TiO₂] blasted, etched)^{15–20} of dental implants.

Recently, 2 bioengineering processes for roughening commercially pure titanium implants have

¹Assistant Professor, Advanced Periodontics, University of Southern California, Los Angeles, California.

²Director, Advanced Periodontics, University of Southern California, Los Angeles, California.

Correspondence to: Dr Alexandre-Amir Aalam, University of Southern California, School of Dentistry, 925 West 34th Street, Room 102, Los Angeles, CA 90089-0641. Fax: +310 477 4998. E-mail: aalam_perio@yahoo.com

Table 1 Descriptive Statistics for Average Bone Loss (in mm) at 24 Months

Region	n	Minimum	Maximum	Mean	SD
Maxilla					
Anterior	26	1.30	1.50	1.3692	0.06493
Premolar	26	1.30	1.50	1.3513	0.05059
Molar	8	1.30	1.40	1.3375	0.51750
Mandible					
Anterior	11	1.30	1.45	1.3441	0.04510
Premolar	21	1.25	1.50	1.3810	0.07496
Molar	19	1.20	1.50	1.3487	0.06794

n = number of patients who had 1 or more implants in each of the 6 regions of the mouth.

gained attention: anodic oxidation²¹ and dual acid-etching.¹¹ Anodic oxidation is an electrochemical process that increases the TiO₂ surface layer and roughness. The implant is immersed in a suitable electrolyte and becomes an anode in an electrochemical cell. When a potential is applied to the sample, ionic transport of charge transfers through the cell, and an electrolytic reaction takes place at the anode, resulting in the growth of an oxide film. The TiUnite dental implant (Brånemark System, Nobel Biocare USA, Yorba Linda, CA) is an anodized commercially pure titanium dental implant. Surface roughness of the TiUnite implant increases from 1 to 2 µm (peak-to-valley distance) at the coronal part to 7 to 10 µm at the apical part.²¹

The dual acid-etching process involves the application of hydrochloric and sulfuric acid to the commercially pure titanium implant. Osseotite (3i/Implant Innovations, West Palm Beach, FL) is a commercially available dental implant bioengineered by a dual acid-etching process. Small peaks and valleys in a uniform pattern with peak-to-peak distances of 1 to 3 µm and peak-to-valley distances of 5 to 8 µm characterize the surface of the implant.¹¹

Although the surface of a machined dental implant (Brånemark System, Nobel Biocare USA), has been described as smooth, turning traces have been found on the surface, conferring upon it a certain rugosity (about 3 to 4 µm).²²

Although there have been in vitro and animal studies on TiUnite and Osseotite implants, there is a paucity of information on the clinical use of these implants. The purpose of the present study was to report clinical experience with and outcomes of dental implants with the 3 types of surfaces described at the University of Southern California's Advanced Education in Periodontology program.

MATERIALS AND METHODS

Patient Selection

The study included 74 patients who received dental implant-supported restorations at the University of Southern California School of Dentistry, Department of Advanced Periodontics. Fifty-eight TiUnite dental implants were evaluated in 25 patients, 52 Osseotite dental implants were evaluated in 27 patients, and 88 machined surface dental implants were evaluated in 22 patients. Exclusion criteria for implant placement included active infection and inflammation and systemic conditions compromising healing. Computerized tomography and periapical radiographs were used to evaluate the potential surgical site and implant sizes.

Surgical Procedures

For appropriate prosthetic position and to optimize the healing potential, site development procedures (sinus elevation, intramembranous osseous transplant) and adaptation of the original surgical protocol (immediate implant placement, utilization of osteotomes, 1-stage surgery) preceded implant placement. Autogenous bone harvested from the intraoral cavity (symphysis, ramus, or tuberosity) was used for all site development procedures requiring bone augmentation, and a 4-month period of healing was allowed prior to implant placement.

Preoperative treatment consisted of prophylactic antibiotic therapy (2 g amoxicillin or 600 mg clindamycin 1 hour before surgery) and oral rinsing with 0.12% chlorhexidine gluconate for 1 minute. Postsurgical medication included 400 mg ibuprofen 4 times a day for 2 days and 500 mg amoxicillin 3 times a day for 7 days.

Clinical Examinations and Recordings

Postoperative observations were recorded on a standardized form by 2 calibrated examiners. Reproducibility was greater than 90%. Radiographic examinations consisted of periapical radiographs obtained at the surgical phase, the restoration phase, and 2 years postloading. Measurements were made from the mesial and distal of the restorative interface to the bone crest at 2 years postrestoration, and an average was calculated. Measurements were made by 2 examiners with a ×7 magnifying loupe (Parlinda, San Bernardino, CA).

Criteria for success included absence of inflammation, pain, discomfort, mobility, and pathologic signs of peri-implant radiolucency.²³ Implant threads were used to measure bone loss around the implant (Fig 1).

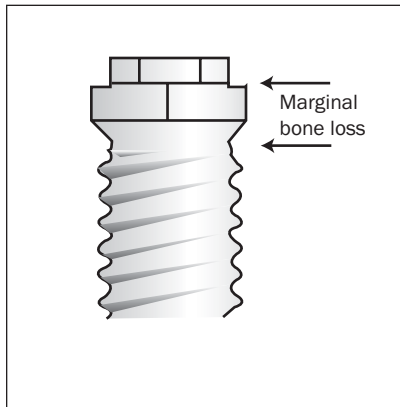


Fig 1 Marginal bone loss was measured from the restorative interface. Implant threads of known dimensions were used to measure bone loss around the implant.

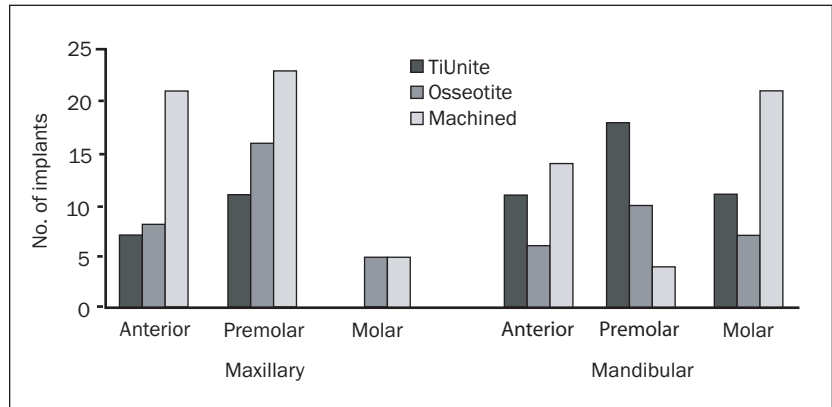


Fig 2 Implant location. Note that none of the TiUnite dental implants were placed in posterior maxillae.

Statistical Analysis

To account for statistical correlation among multiple implants in the same subject, a “per patient” mode of analysis was used. Table 1 describes the number of patients who had 1 or more implants in each of the 6 regions of the mouth. A 1-way analysis of variance (ANOVA) was conducted regarding bone loss by type of implant as well as by area of the mouth.

In addition, differences in mean bone loss were tested for bone density, category, gender, and smoking status using Student *t* tests. Preliminary analysis demonstrated that correlations between these dichotomous variables, region of the mouth, age, and bone loss were low and did not warrant further analysis.

RESULTS

Patient Selection and Surgical Procedures

In the TiUnite group, 25 patients (17 male, 8 female), from 23 to 69 years old (mean age = 50.7 ± 14.0 y) received 58 dental implants. In 17 patients, implants were placed after ridge expansion ($n = 5$, 29.4%) or sinus elevation ($n = 3$, 17.6%), using a combination of drilling and manual osteotomy. Intramembranous osseous transplants ($n = 4$, 23.5%) for site development as well as immediate implant placement after tooth extraction were performed ($n = 5$, 29.4%) when indicated as described by Nowzari,²⁴ Schincaglia and Nowzari,²⁵ and D’Addona and Nowzari.²⁶ A 1-stage approach was applied in 17 patients based on primary mechanical stability (45 Ncm or more) and the soft tissue condition evaluation at the time of implant placement.

In the Osseotite group, 27 patients (14 male, 13 female), from 27 to 68 years old (mean age = 46.9 ± 13.3 y) received 52 dental implants. In 14 patients, implants were placed after ridge expansion ($n = 6$, 42.9%), sinus elevation ($n = 3$, 21.4%), intramembranous osseous transplant ($n = 1$, 7.1%), or immediate implant placement after tooth extraction ($n = 4$, 28.6%). A 1-stage approach was applied in 11 patients based on the primary mechanical stability and the soft tissue condition evaluation at the time of implant placement.

In the machined group, 22 patients (10 male, 12 female) from 31 to 80 years old (mean age = 60.7 ± 15.5 y) received 88 dental implants. In 16 patients, implants were placed after ridge expansion ($n = 5$, 31.2%), sinus elevation ($n = 3$, 18.7%), intramembranous osseous transplant ($n = 4$, 25.0%), or immediate implant placement after tooth extraction ($n = 4$, 25.0%). A 1-stage approach was applied in 17 patients based on the primary mechanical stability and the soft tissue condition evaluation at the time of implant placement.

Implant Location

Eighteen TiUnite dental implants (31.0%) were placed in maxillae, and 40 (69.0%) were placed in mandibles. For the Osseotite group, 29 implants (57.8%) were placed in maxillae and 23 (44.2%) were placed in mandibles. Forty-nine machined implants (55.7%) were placed in maxillae, and 39 implants (44.3%) were placed in mandibles (Fig 2).

Implant Length

Implants of 6 different lengths ranging from 7 to 15 mm were utilized. The most frequently used length

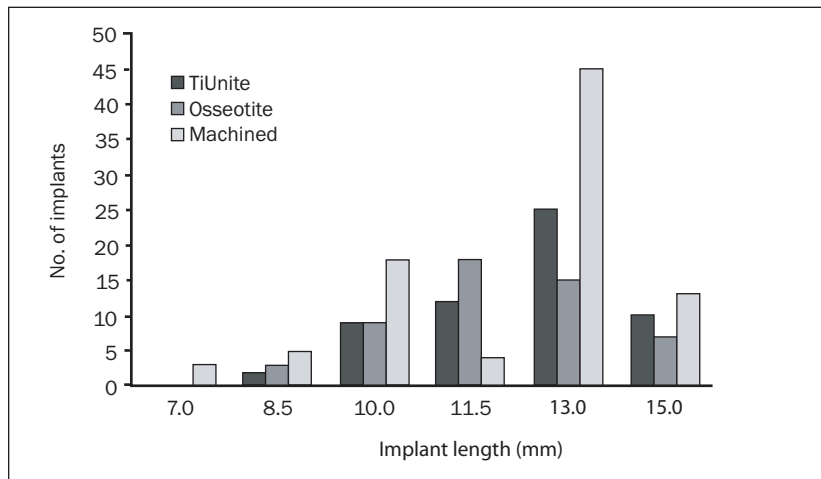


Fig 3 Implant length. Note that only in the machined group were 7-mm-long implants used.

was 13 mm (48.0% of all implants placed). The 13-mm length was most frequently used in the TiUnite and machined groups; 43.1% and 51.5%, respectively, of all implants placed in these groups were 13 mm long. The 11.5 mm length was the most common length placed in the Osseotite group; 34.6% of Osseotite implants placed were 11.5 mm long (Fig 3).

Smoking

Patients smoking more than 10 cigarettes per day were considered smokers in this study. Four patients (16%) in the TiUnite group, 6 (22.2%) in the Osseotite group, and 6 (27.3%) in the machined group were smokers.

Bone Density

For purposes of this study, the Lekholm and Zarb²⁷ classification of bone density was modified and simplified. Bone types 1 and 2 were classified as high-density bone, and types 3 and 4 were considered low-density bone. Twelve patients (48.0%) in the TiUnite group, 15 (55.6%) in the Osseotite group, and 8 (36.4%) in the machined group presented with high-density bone.

Bone Level

A "per patient" mode of analysis was conducted to identify the patients who had 1 or more implants in each of the 6 regions of the mouth. The regions where the most patients ($n = 26$) needed at least 1 implant were the anterior maxilla and the premolar region of the maxilla. The lowest average bone loss (1.34 mm) was in the anterior mandible and in the molar region of the maxilla; the highest average bone loss (1.38 mm) was in the premolar area of the mandible (Table 1).

A 1-way ANOVA of bone loss by type of implant (group) was conducted separately on each area of the

oral cavity. The independent variable was the implant group, and the dependent variable was the average bone loss for the specific region of the mouth. Although the results of the 1-way ANOVA for the premolar region of the maxilla approached significance, ($F [2, 23] = 2.882, P = .076$), the results were not statistically significant for any of the 6 regions of the mouth ($P < .05$). A post-hoc test revealed that the greatest difference in bone loss appeared to be between the TiUnite and machined groups ($P = .079$). No significant differences in bone loss in regard to bone density, gender, or smoking status were observed.

Prostheses

A total of 98 screw-retained prostheses (27 in the TiUnite group, 34 in the Osseotite group, and 37 in the machined group) were fabricated and classified into 4 categories:

- *Single-unit prostheses*: Twelve (44.0%) were seated in the TiUnite group, 22 (64.0%) in the Osseotite group, and 14 (38.0%) in the machined group.
- *Short-span fixed partial dentures*: Seven (26.0%) prostheses were seated in the TiUnite group, 6 (18.0%) in the Osseotite group, and 9 (24.0%) in the machined group.
- *Long-span fixed partial dentures*: Seven (26.0%) prostheses were seated in the TiUnite group, 6 (18.0%) in the Osseotite group, and 14 (38.0%) in the machined group.
- *Overdentures*: One overdenture prosthesis was seated in the TiUnite group.

The long-span fixed partial denture (38%) was most frequently delivered in the machined group, whereas the single-unit prosthesis was most frequently delivered in the Osseotite group (64%) (Fig 4).

DISCUSSION

The present study evaluated clinical experience with and outcomes of TiUnite, Osseotite, and machined dental implant surfaces. All implants were clinically successful,²⁶ and the results were in accordance with previous studies.

In a 3-year study, Olsson and associates²⁸ evaluated 550 machined-surface implants placed in 103 jaws (33 maxillae and 70 mandibles) and reported a survival rate of 100% for the mandible and 88% for the maxilla. Friberg and colleagues²⁹ evaluated 180 machined implants placed in 21 mandibles and reported a success rate of 98.9%. High success rates (more than 90%) for machined-surface implants have been reported by several other investigators.^{2,30–32} In contrast, Jaffin and Berman³³ reported high failure rates for machined-surface implants in poor-quality bone (56% in the maxilla and 63% in the mandible) over a 5-year follow-up period.

Khang and colleagues³⁴ reported a 98.4% success rate in good-quality bone and a 98.1% success rate in poor-quality bone using the Osseotite implant over a 60-month trial. The high success rate in poor-quality bone was attributed to the increased bone-to-implant contact promoted by roughened dental implant surfaces.^{11,19} In the present study, 63.4% of the machined dental implants were placed in low-density bone (type 3 or 4),²⁷ with clinical success rates similar to those achieved with TiUnite and Osseotite. Forty-eight percent of the TiUnite implants and 44.5% of the Osseotite implants were placed in low-density bone.

The high biologic and mechanical success rates of both machined dental implants and implants with roughened surfaces such as TiUnite and Osseotite could be attributed to appropriate surgical and restorative phases, emphasizing the significance of proper diagnosis-based treatment planning.

Smoking did not seem to affect the success rate in the present study. However, Bain and Moy³⁵ reported a failure rate of 11.3% in smokers compared to 4.8% in nonsmokers. More recently, Bain and associates³⁶ reported no difference and attributed the high success rate of 98.5% for both groups to a roughened implant surface.

De Bruyn and Collaert³⁷ evaluated machined surface dental implants in the mandibles of smoking and nonsmoking patients and reported only 1 failure of 208 implants placed. They reported higher failure rates in the maxilla: 10 of 244 implants failed; 7 failed in smokers and 3 in nonsmokers. The impact and the significance of smoking in implant dentistry is an area where further study is needed.

Seventeen patients in the TiUnite group, 14 patients in the Osseotite group, and 17 patients in

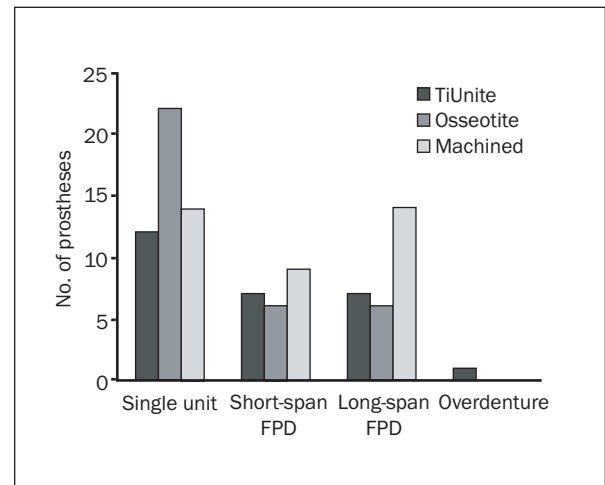


Fig 4 Prosthesis distribution. FPD = fixed partial denture.

the machined group received dental implants placed after grafting with autogenous bone blocks,^{26,38} sinus elevation,³⁹ or ridge expansion,²⁵ or immediately after extraction.^{5–9} Because of the high clinical success rates of all implant surfaces, the significance of enhanced surface properties could not be measured among the groups.

The differences in bone loss between the 3 groups of implants were not statistically significant ($P > .05$). Although not statistically significant ($P > .05$), the greatest difference in bone loss was found between the TiUnite group and the machined group ($P = .079$). The slightly greater level of bone loss observed in the TiUnite group could be attributed to the roughened surface reaching the most coronal part of the implant, potentializing microbial colonization.

It is important to note that the total sample sizes for each region of the mouth ranged from 11 to 26. Therefore, there may not have been enough power to detect significant differences.

CONCLUSION

Within the limitations of the present study, TiUnite, Osseotite, and machined dental implants had similar short-term clinical outcomes. No statistically significant differences in bone loss could be detected among implant groups or among the different regions of the oral cavity. The present data underlined the significance of surgical and prosthetic treatment planning.

REFERENCES

- Brånemark P-I. Introduction to osseointegration. In: Brånemark P-I, Zarb G, Albrektsson T (eds). *Tissue-Integrated Prostheses: Osseointegration in Clinical Dentistry*. Chicago: Quintessence, 1995:11–76.
- Albrektsson T, Dahle E, Enbom L, et al. Osseointegrated oral implants. A Swedish multicenter study of 8,139 consecutively inserted Nobelpharma implants. *J Periodontol* 1988;59:287–296.
- Mayer TM, Hawley CE, Gunsolley JC, Feldman S. The single-tooth implant: A viable alternative for single-tooth replacement. *J Periodontol* 2002;73:687–693.
- Lundgren S, Moy PK, Beumer J III, Lewis S. Surgical consideration for endosseous implants in the craniofacial region: A 3-year report. *Int J Oral Maxillofac Surg* 1993;22:272–277.
- Gelb DA. Immediate implant surgery: Three-year retrospective evaluation of 50 consecutive cases. *Int J Oral Maxillofac Implants* 1993;8:388–399.
- Schwartz-Arad D, Chaushu G. Full-arch restoration of the jaw with fixed ceramometal prostheses. *Int J Oral Maxillofac Implants* 1998;13:819–825.
- Rosenquist B, Grenthe B. Immediate placement of implants into extraction sockets: Implant survival. *Int J Oral Maxillofac Implants* 1996;11:205–209.
- Wilson TG Jr, Schenk R, Buser D, Cochran D. Implants placed in immediate extraction sites: A report of histologic and histometric analyses of human biopsies. *Int J Oral Maxillofac Implants* 1998;13:333–341.
- Tarnow DP, Fletcher P. The two-to-three month postextraction placement of root form implants: A useful compromise. *Implants Clin Rev Dent* 1993;2:1–6.
- O'Sullivan D, Sennerby L, Meredith N. Measurements comparing the initial stability of five designs of dental implants: A human cadaver study. *Clin Implant Dent Related Res* 2000;2:85–92.
- Lazzara R, Porter SS, Testori T, Galante J, Zetterqvist L. A prospective multicenter study evaluating loading of Osseotite implants two months after placement: One-year results. *J Esthet Dent* 1998;10:280–289.
- Becker W, Becker BE, Israelson H, et al. One-step surgical placement of Brånemark implants: A prospective multicenter clinical study. *Int J Oral Maxillofac Implants* 1997;12:454–462.
- Buser D, Weber HP, Lang NP. Tissue integration of non-submerged implants. 1-year results of a prospective study with 100 ITI hollow-cylinder and hollow-screw implants. *Clin Oral Implants Res* 1990;1:33–40.
- Binon PP. Implants and components: Entering the new millennium. *Int J Oral Maxillofac Implants* 2000;15:76–94.
- Buser D, Schenk RK, Steinemann S, Fiorellini JP, Fox CH, Stich H. Influence of surface characteristics on bone integration of titanium implants. A histomorphometric study in miniature pigs. *J Biomed Mater Res* 1991;25:889–902.
- Deporter DA, Watson PA, Pilliar RM, Chipman ML, Valiquette N. A histological comparison in the dog of porous-coated vs. threaded dental implants. *J Dent Res* 1990;69:1138–1145.
- Block MS, Finger IM, Fontenot MG, Kent JN. Loaded hydroxylapatite-coated and grit-blasted titanium implants in dogs. *Int J Oral Maxillofac Implants* 1989;4:219–225.
- Wennerberg A, Albrektsson T. Suggested guidelines for the topographic evaluation of implant surfaces. *Int J Oral Maxillofac Implants* 2000;15:331–344.
- Leimola-Virtanen R, Peltola J, Oksala E, Helenius H, Happonen RP. ITI titanium plasma-sprayed screw implants in the treatment of edentulous mandibles: A follow-up study of 39 patients. *Int J Oral Maxillofac Implants* 1995;10:373–378.
- Gross KA, Berndt CC, Iacono VJ. Variability of hydroxyapatite-coated dental implants. *Int J Oral Maxillofac Implants* 1998;13:601–610.
- Albrektsson T. *Appl Osseointegration Res* 2000;1:3–33.
- Wennerberg A. On Surface Roughness and Implant Incorporation [thesis]. Göteborg, Sweden: Göteborg Univ, 1996.
- Albrektsson T, Zarb G, Worthington P, Eriksson AR. The long-term efficacy of currently used dental implants: A review and proposed criteria of success. *Int J Oral Maxillofac Implants* 1986;1:11–25.
- Nowzari H. Esthetic implant dentistry. *Compend Contin Educ Dent* 2001;22:643–650.
- Schincaglia GP, Nowzari H. Surgical treatment planning for the single-unit implant in aesthetic areas. *Periodontol* 2000;27:162–182.
- D'Addona A, Nowzari H. Intramembranous autogenous osseous transplants in aesthetic treatment of alveolar atrophy. *Perio* 2000;27:148–161.
- Lekholm U, Zarb GA. Patient selection and preparation. In: Brånemark P-I, Zarb G, Albrektsson T (eds). *Tissue-Integrated Prostheses: Osseointegration in Clinical Dentistry*. Chicago: Quintessence, 1985:199–209.
- Olsson M, Gunne J, Astrand P, Borg K. Bridges supported by free-standing implants versus bridges supported by tooth and implant: A five-year prospective study. *Clin Oral Implants Res* 1995;6:114–121.
- Friberg B, Grondahl K, Lekholm U. A new self-tapping Brånemark implant: Clinical and radiographical evaluation. *Int J Oral Maxillofac Implants* 1992;7:80–85.
- Adell R, Lekholm U, Rockler B, Brånemark P-I. A 15-year study of osseointegrated implants in the treatment of edentulous jaw. *Int J Oral Surg* 1981;10:387–416.
- Lindquist L, Rockler B, Carlsson G. Bone resorption around fixtures in edentulous patients treated with mandibular fixed tissue-integrated prostheses. *J Prosthet Dent* 1988;59:59–63.
- Naert I, Quirynen M, et al. A study of 589 consecutive implants supporting complete fixed prostheses. Part II: Prosthetic aspects. *J Prosthet Dent* 1992;68:949–956.
- Jaffin RA, Berman CL. The excessive loss of Brånemark fixtures in type IV bone: A 5-year analysis. *J Periodontol* 1991;62:2–4.
- Khang W, Feldman S, Hawley CE, Gunsolley J. A multi-center study comparing dual acid-etched and machined-surfaced implants in various bone qualities. *J Periodontol* 2001;10:1384–1390.
- Bain CA, Moy PK. The association between the failure of dental implants and cigarette smoking. *Int J Oral Maxillofac Implants* 1993;8:609–615.
- Bain CA, Weng D, Meltzer A, Kohles SS, Stach RM. A meta-analysis evaluating the risk for implant failure in patients who smoke. *Compend Contin Educ Dent* 2002;23:695–699, 702, 704.
- De Bruyn H, Collaert B. The effect of smoking on early implant failure. *Clin Oral Implants Res* 1994;5:260–264.
- Tolman DE. Reconstructive procedures with endosseous implants in grafted bone: A review of the literature. *Int J Oral Maxillofac Implants* 1995;10:275–294.
- Jensen OT, Shulman LB, Block MS, Iacono VJ. Report of the Sinus Consensus Conference of 1996. *Int J Oral Maxillofac Implants* 1998;13(suppl):11–45.